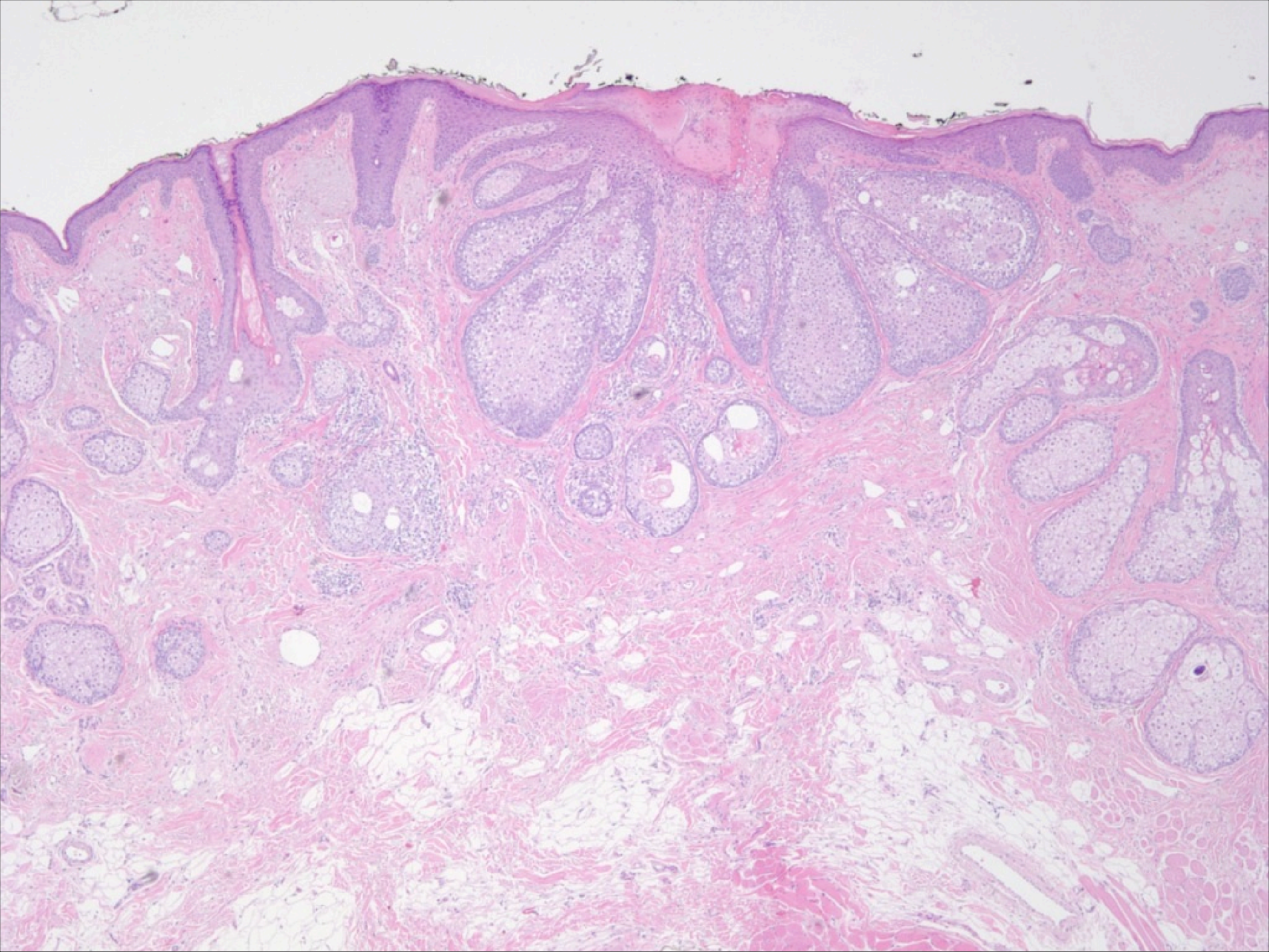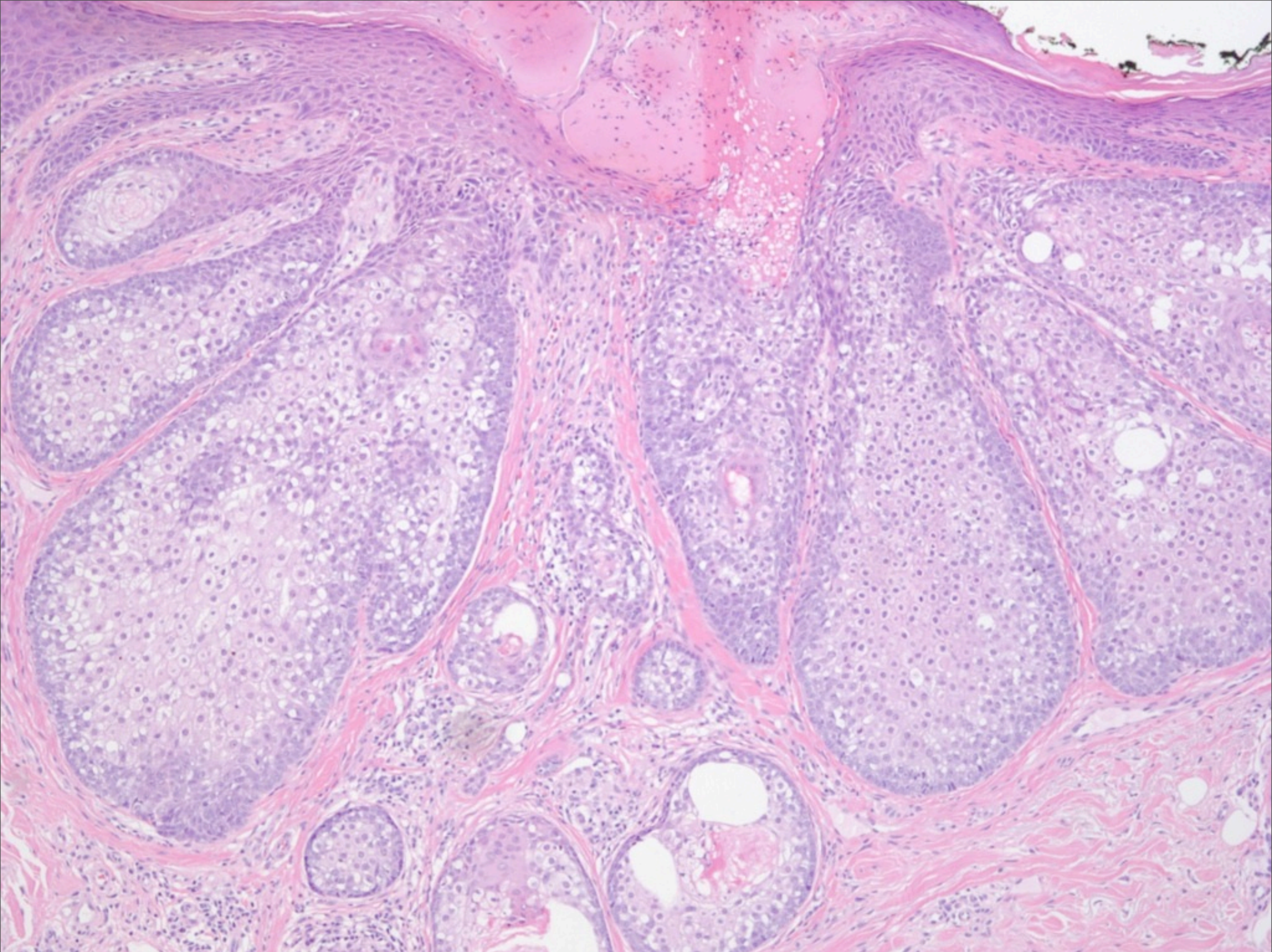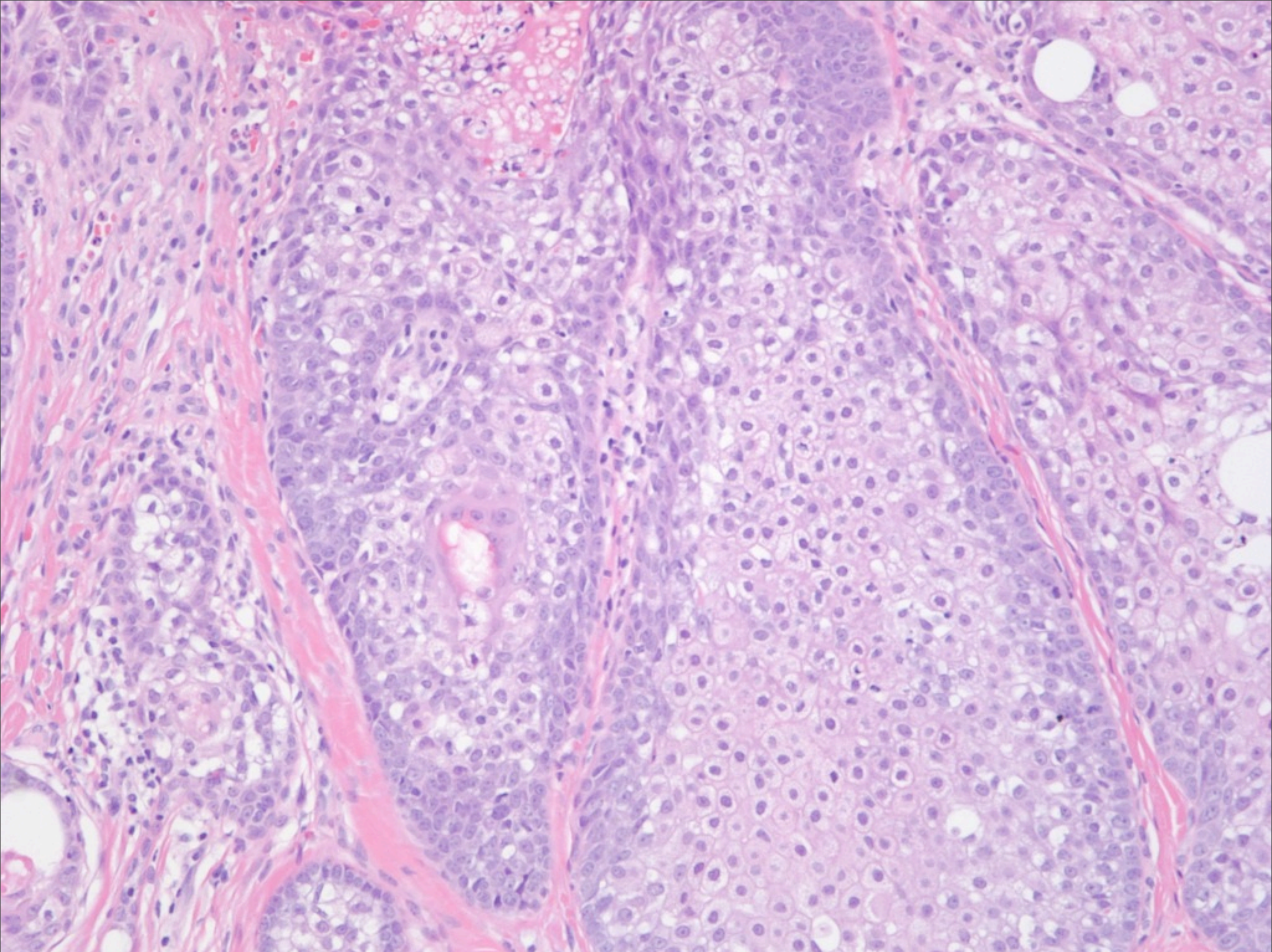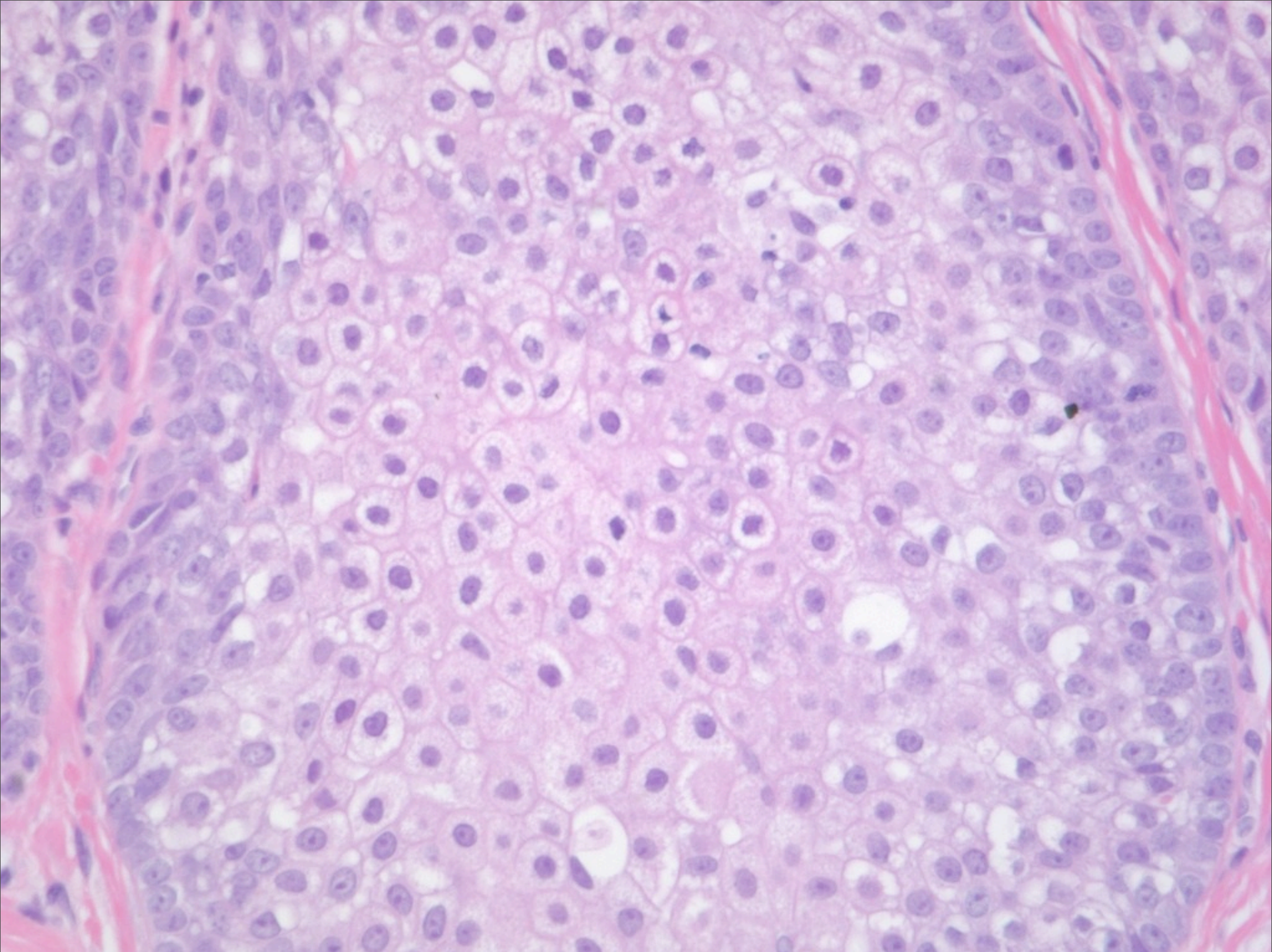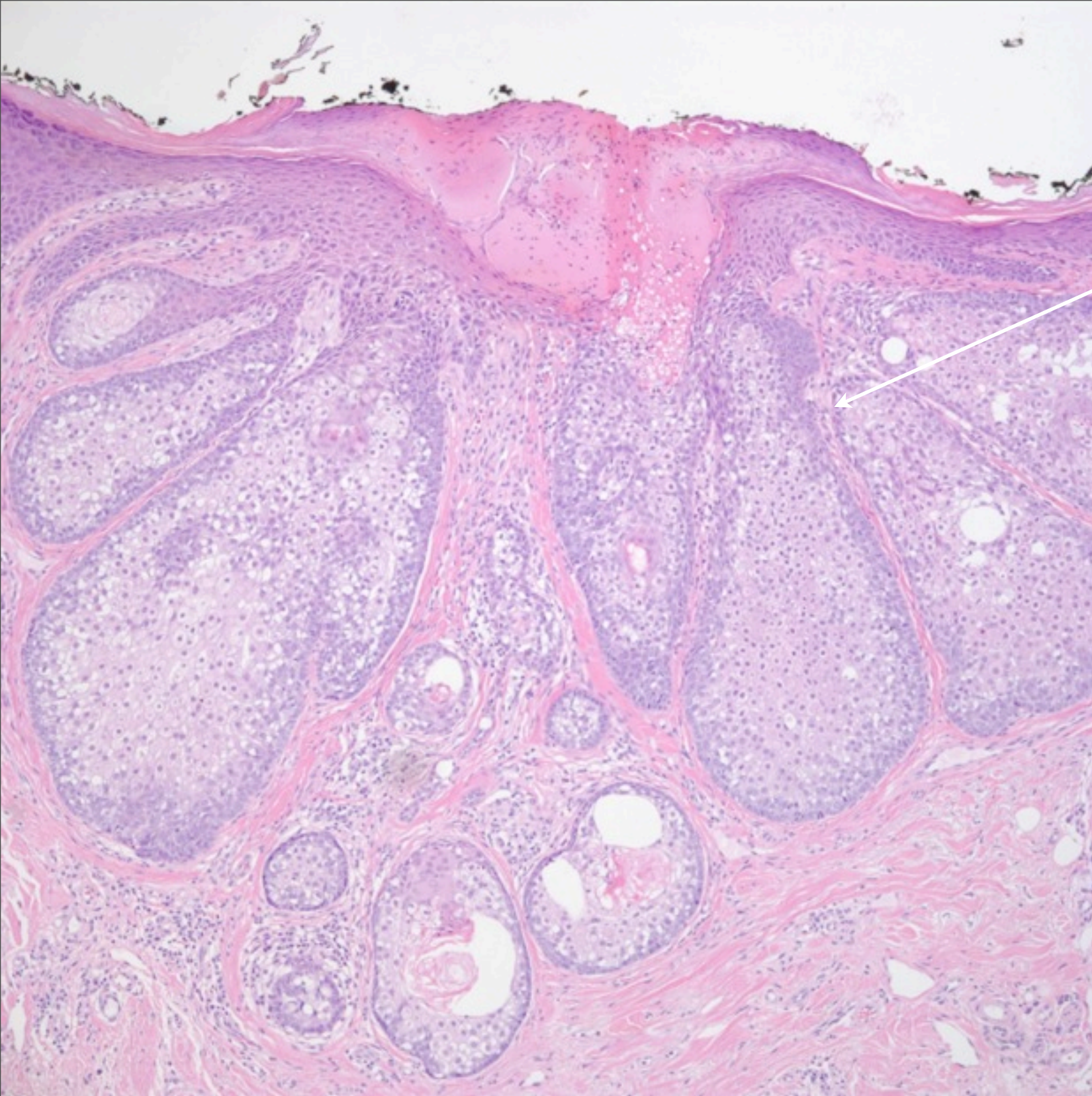


Sebaceous Adenoma



Basal layer
surrounding sebocytes

Minimal Atypia

Circumscribed lobules of mature sebaceous lobules